Cryptorchidism With Short Spermatic Vessels: Staged Orchiopexy Preserving Spermatic Vessels

A. Dessanti, D. Falchetti, M. Iannuccelli, S. Milianti, C. Altana, A. R. Tanca, M. Ubertazzi, G. P. Strusi and M. Fusillo

From the Department of Pediatric Surgery (AD, MI, MU, MF) and Institute of Radiology (GPS), Azienda Ospedaliero-Universitaria, University of Sassari, Sassari and Department of Pediatric Surgery, Spedali Civili, Brescia (DF, SM, CA, ART), Italy

Purpose: Patients with cryptorchidism can have such short spermatic vessels that it is impossible to place the testicle in a satisfactory scrotal position using conventional orchiopexy. In these cases the most commonly used operation is 1 to 2-stage Fowler-Stephens orchiopexy. We present our surgical experience using staged inguinal orchiopexy without section of the spermatic vessels in patients with short spermatic vessels.

Materials and Methods: We used 2-stage inguinal orchiopexy in 38 children with intra-abdominal testis or testis peeping through the internal ring and short spermatic vessels (7 bilateral). Spermatic vessels were not sectioned, but were lengthened through progressive traction of the spermatic cord wrapped in polytetrafluoroethylene pericardial membrane (Preclude®). In the first stage we mobilized the spermatic cord in the retroperitoneal space and then wrapped it in the polytetrafluoroethylene membrane. We subsequently attached the testis to the invaginated scrotal bottom. At 9 to 12 months we performed the second stage, which involved removing the polytetrafluoroethylene membrane.

Results: From the first to the second stage we observed progressive descent of the testicle toward the scrotum. At 1 to 8-year followup after the second stage all 45 testicles were palpable in a satisfactory scrotal position with stable or increased testicular volume.

Conclusions: This technique represents an alternative to Fowler-Stephens orchiopexy, which can be associated with a greater risk of testicular ischemia.

Key Words: cryptorchidism, testis, urogenital abnormalities, urogenital surgical procedures

Abbreviations and Acronyms

FS = Fowler-Stephens

PTFE = polytetrafluoroethylene

Submitted for publication January 12, 2009.

CRYPTORCHIDISM cases are usually divided into 2 subgroups—those with palpable and nonpalpable testes. In patients with a palpable testis the gonad can usually be fixed easily in the hemiscrotum using conventional inguinal orchiopexy.[1] Nonpalpable testis occurs in 20% to 30% of cases.[2] Most of these testes are present in the abdomen or inguinal canal, with 20% to 45% being absent or vanishing secondary to intrauterine or perinatal torsion.[1–4]

Nonpalpable testes and, rarely, palpable testes can have an extremely short spermatic vessel that does not allow them to be placed in a satisfactory scrotal position using standard orchiopexy performed via an inguinal incision or laparoscopy.

0022-5347/09/1823-1163/0
THE JOURNAL OF UROLOGY®

Vol. 182, 1163-1168, September 2009
Printed in U.S.A.
DOI:10.1016/j.juro.2009.05.050

For these select cases, which represent approximately 3% of all undescended testes,[3,5] the surgical solution proposed is inguinal or laparoscopic FS orchiopexy.[6] We present our experience with cryptorchidism involving extremely short spermatic vessels, where we used staged inguinal orchiopexy without section of the spermatic vessels. These vessels were lengthened through progressive traction after being wrapped in an anti-adhesion PTFE pericardial membrane.

MATERIALS AND METHODS

We reviewed the clinical charts of children with cryptorchidism treated at 2 pediatric surgery units from 1997 to 2006. Of 1,698 patients 60 (3.5%) had such short spermatic vessels that they could not be placed in a satisfactory scrotal position using standard orchiopexy. Of this group only the patients surgically treated by the 2 senior authors (AD, DF) were analyzed. Of 38 cases 7 were bilateral, for a total of 45 testes. Of the testes 34 were intra-abdominal and 11 were peeping through the internal ring. Patient age was 1 to 5 years (average 35 months). In all cases we located the testicle through the open inguinal procedure only, preceded by preoperative ultrasound in which we were able to evaluate the position and volume of the testicle. Parents gave informed consent for the surgery.

Surgical Technique

An oblique inguinal incision is made in the skin crease. When the external oblique fascia is opened the processus vaginalis is located (normally open in these cases). It is isolated beyond the internal inguinal ring, as closely as possible, therefore involving the retroperitoneal space. Once the processus vaginalis is opened the testicle is located. The testicle normally has a short spermatic cord that still allows for some mobility in the abdomen. Keeping the processus vaginalis and testicle in light traction, the processus vaginalis is cut in a circle proximal to the testicle so that it is possible to isolate and mobilize the testicle and its spermatic cord in the retroperitoneal space. To perform this maneuver, after dissecting free and ligating the processus vaginalis at the level of the internal ring, the posterior peritoneum is protected by a long, thin Langenback retractor. Dissection of the spermatic cord and spermatic vessels is carried out mainly by dividing the tethering bands of lateral spermatic fascia until their maximum length is obtained.

When it is impossible to place the gonad in a satisfactory scrotal position (when the testicle cannot be brought past the pubic tubercle) the spermatic cord is wrapped along its entire length in an anti-adhesion PTFE pericardial membrane, which is fashioned into a conduit using a continuous absorbable polydioxanone suture (Vicryl™, fig. 1).

The Preclude pericardial membrane is a biocompatible sheet of expanded PTFE that has a nominal pore size of less than 1 nm and a thickness of 0.1 mm. This application is normally indicated in reconstruction of the pericardium and other areas because it does not develop adhesions.[7] To cover a longer span of the mobilized spermatic elements in the retroperitoneal space, the PTFE membrane is sometimes tailored individually around the spermatic vessels and vas deferens. Through the inguinal incision the testicle is fixed to the scrotal bottom, which is everted for this purpose. The fixing sutures (polydioxanone monofilament 5-zero, PDS™ II) are placed between the scrotal skin and, superficially, the tunica albuginea in the space between the testis and tail of the epididymis (fig. 2).

To minimize ischemic lesions on the scrotal skin and better distribute the traction the scrotal skin exerts on the testicle and spermatic cord, the sutures include a small synthetic pledget on the outside of the scrotal skin. When fixed the invaginated scrotal bottom, which appears creased and folded inward, exerts strong traction on the spermatic cord. With time this inward folding reduces together with descent of the testicle caused by lengthening of the spermatic cord.

An additional colored nonabsorbable nylon suture is fixed to the distal part of the PTFE conduit as a marker. The other end of the nylon suture is stitched to the derma, near the surgical incision, to facilitate identifi-

Figure 1. Spermatic vessels and vas deferens are dissected deep within retroperitoneal space. Extremely short spermatic cord is then wrapped in PTFE membrane and fashioned into conduit.

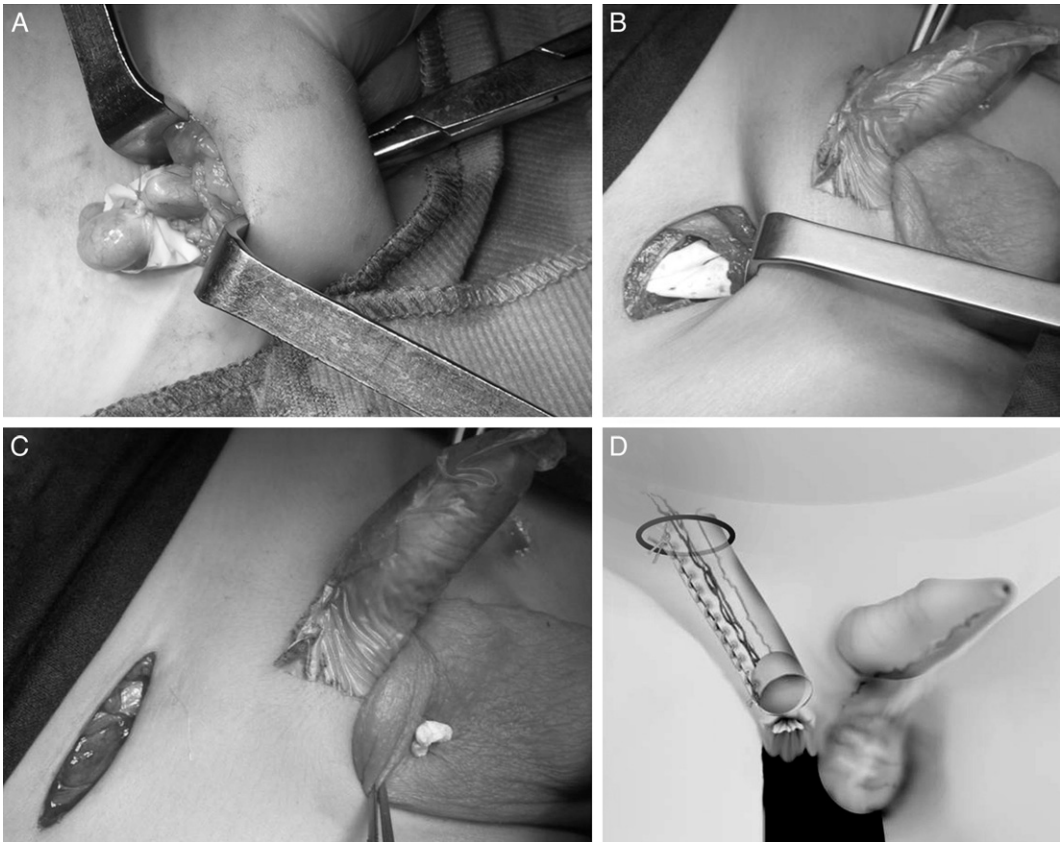

Figure 2. Testis is fixed to skin of bottom of scrotum, which is invaginated. In suture small synthetic plug is also included to minimize local ischemia.

cation and removal of the PTFE membrane during the second stage. The pledget normally falls off spontaneously after 30 days. Only the testis is not wrapped in the PTFE membrane, to facilitate adhesion to the scrotal floor.

The second stage is performed at 9 to 12 months. If the testicle is in a satisfactory scrotal position, the purpose of the second stage is to remove the PTFE membrane. The previous incision is reused and the inguinal canal is not usually open. The PTFE conduit, easily identified by the colored nylon suture stitched to the derma during the first stage, is then removed. If the testicle is in a high unsatisfactory scrotal position after opening the inguinal canal and removing the PTFE membrane, the testicle is repositioned in the scrotal cavity after its re-isolation.

All children underwent clinical followup evaluation, which included echo color Doppler study, after the first and second stages. No other technique, including FS, was used in cases of testicles with extremely short spermatic cords.

RESULTS

No intraoperative or postoperative complications occurred. In the 7 bilateral cases both testicles were operated on together. From the first to second stage the inward folding of the scrotum bottom was reduced in all cases with progressive descent of the testes toward the scrotum. At the second stage, after removal of the PTFE membrane, the spermatic cord was always free of adhesions, loose and mobile down the inguinal canal (fig. 3). All 45 gonads showed adhesion with the scrotum, with 37 in a satisfactory scrotal position and 8 (18%) in an unsatisfactory high scrotal position. In these cases during this surgical stage we observed that the traction of the scrotal bottom on the testicle and spermatic cord determined a slow detachment of the scrotal bottom from the testicle, as if to form a relatively long scrotal ligament. In these patients it was necessary to reopen the inguinal canal distally, re-isolate the testicle from the scrotal bottom and reposition it in a satisfactory scrotal position. This surgical dissection was not complex in any case, since the risk of damaging the spermatic vessels and vas deferens during their re-isolation was minimal because the spermatic cord was free from adhesions up to the internal inguinal ring.

Figure 3. Second stage. PTFE membrane is removed. Spermatic cord is mobile and extendible because it is free of adhesions.

There was no difference in testicular position at the second stage in relation to the shape of the proximal part of the conduit (single or double around vessels and vas). At 1 to 8 years of followup (mean 3) after the second stage all 45 testicles were palpable and still firmly in a satisfactory scrotal position (fig. 4). Echo color Doppler revealed good blood supply to all testes and stable or increased testicular volume compared to preoperative and perioperative ultrasound.

DISCUSSION

Surgical treatment of nonpalpable testes with short spermatic vessels is still a challenge and is frequently debated by pediatric surgeons. Corkery[8] and later Steinhardt et al[9] reported a 2-stage orchiopexy technique involving wrapping of the spermatic cord in a silastic sheet while the testis was fixed to the pubic bone. This method was used with the sole aim of reducing the risk of iatrogenic injuries of the spermatic cord during the second stage of orchiopexy. Orthotopic autotransplantation was proposed to recreate a blood supply to the testicle and prevent the vanishing complication but the technique was rejected due to its unsatisfactory results and complexity.[10,11]

Currently the most widely used orchiopexy technique is the 1 or 2-stage FS method.[6] This approach requires interruption of the spermatic vessels to bring down the testicle into the correct scrotal position. In this method vascularization of the testis is thus supplied only by the vasa deferentia, with a consequent risk of testicular hypotrophy or atrophy ranging from 2% to 33%.[3,4,12–20]

Because it requires division of the spermatic vessels, the FS procedure represents a management dilemma, especially in bilateral cases. The decision to use FS vs standard orchiopexy is based solely on visual observation during video assisted or open surgery.[5,21] Therefore, the decision cannot be made after extensive surgical isolation of the spermatic cord. In fact, extensive isolation of the spermatic cord would result in interruption of the vasa deferentia, guaranteeing lack of vascularization of the gonad if FS is chosen. Thus, this procedure can be misused, even being applied in testicles that could benefit from standard orchiopexy without the risks linked to sectioning of the spermatic vessels. For the same reasons a positive visual evaluation regarding potential lengthening of the spermatic cord after extensive mobilization could be incorrect, with the consequent risks of 1) descent of the testicle to an unsatisfactory high inguinoscrotal position, requiring a standard second stage orchiopexy and 2) extreme mobilization of the spermatic cord, with the consequent risk of hypotrophy or atrophy of the testicle due to ischemia.

The methods and purposes of our surgical technique are based on the following principles. The technique can be performed after extended retroperitoneal mobilization of the spermatic elements, when lengthening of the spermatic cord achieved is unsatisfactory. The PTFE conduit envelops the entire length of the spermatic cord from its retroperitoneal tract to prevent adhesions to surrounding tissues. Progressive elongation of the spermatic cord and consequent descent of the testis into the scrotal position between the first and second stage are due to the constant and nonischemizing traction exerted by the invaginated scrotal skin on the entire spermatic cord, which is free of adhesions.

From our experience the PTFE membrane is so thin (0.1 mm) that it does not cause symptomatic hernias. Disengagement of the gonad at the second stage occurred in about 18% of testes, with the gonad appearing stuck in a high scrotal position.

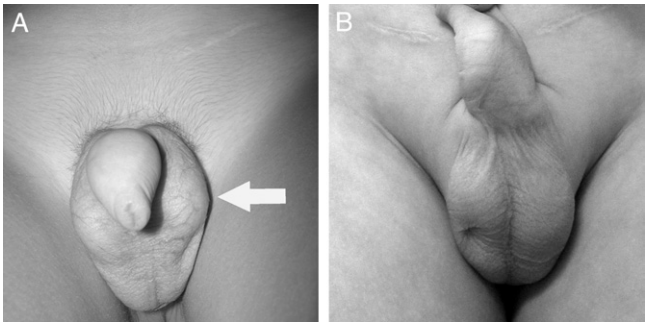

Figure 4. Final scrotal position of testes 3 years after second stage. *A*, left unilateral orchiopexy. *B*, bilateral orchiopexy.

In these cases surgical dissection was not complex and above all did not risk any lesion of the spermatic cord, which was free of adhesions and, therefore, mobile and extendable. This finding allowed for easy re-isolation of the testis, which was the only structure exhibiting adhesions, and definitive re-fixation to the scrotal skin in a correct position. At long-term followup all children demonstrated a gonad with a positive echo color Doppler signal of spermatic vessels and stable or increased testicular volume.

In conclusion, this technique represents an alternative to FS, which can be associated with a greater risk of testicular ischemia. Ischemia causes not only disappearance of the gonad, but also its insufficient development in adulthood, an aspect that has not been sufficiently quantified in long-term studies.

REFERENCES

1. Hutson JM: Undescended testis, torsion, and varicocele. In: Pediatric Surgery, 6th ed. Edited by JL Grosfeld, JA O'Neill Jr, EW Fonkalsrud et al. Philadelphia: Mosby Elsevier 2006; vol 2, chapt 75, pp 1193–1214.
2. Kogan S: Cryptorchidism. In: Clinical Pediatric Urology, 3rd ed. Edited by PP Kelalis, LR King and AB Belman. Philadelphia: WB Saunders Co 1992; vol 2, chapt 23, pp 1050–1083.
3. Kirch AJ, Escala J, Duckett JW et al: Surgical management of the nonpalpable testis: the Children's Hospital of Philadelphia experience. J Urol 1998; **159:** 1340.
4. Zerella JT and McGill LC: Survival of nonpalpable undescended testicles after orchiopexy. J Pediatr Surg 1993; **28:** 251.
5. Banieghbal B and Davies M: Laparoscopic evaluation of testicular mobility as a guide to management of intra-abdominal testes. World J Urol 2003; **20:** 343.
6. Fowler R and Stephens FD: The role of testicular vascular anatomy in the salvage of high undescended testes. Aust N Z J Surg 1959; **29:** 92.
7. Dessanti A, Caccia G, Iannuccelli M et al: Use of "Gore-Tex surgical membrane" to minimize surgical adhesions in multistaged extrathoracic esophageal elongation for esophageal atresia. J Pediatr Surg 2000; **35:** 610.
8. Corkery JJ: Staged orchiopexy—a new technique. J Pediatr Surg 1975; **10:** 515.
9. Steinhardt GF, Kroovand RL and Perlmutter AD: Orchiopexy: planned 2-stage technique. J Urol 1985; **133:** 434.
10. Wacksman J, Dinner M and Handler M: Results of testicular autotransplantation using the microvascular technique: experience with 8 intra-abdominal testes. J Urol 1982; **128:** 1319.
11. Frey P and Bianchi A: Microvascular autotransplantation of the intra-abdominal testes. Prog Pediatr Surg 1989; **23:** 115.
12. Kogan SJ, Houman BZ, Reda EF et al: Orchiopexy of the high undescended testis by division of the spermatic vessels: a critical review of 38 selected transections. J Urol 1989; **141:** 1416.
13. Diamond DA and Caldamone AA: The value of laparoscopy for 106 impalpable testes relative to clinical presentation. J Urol 1992; **148:** 632.
14. Elder JS: Two-stage Fowler-Stephens orchiopexy in the management of intra-abdominal testes. J Urol 1992; **148:** 1239.
15. Corbally MT, Quinn FJ and Guiney EJ: The effect of two-stage orchiopexy on testicular growth. J Urol 1993; **72:** 376.
16. Docimo SG: The results of surgical therapy for cryptorchidism: a literature review and analysis. J Urol 1995; **154:** 1148.
17. Lindgren BW, Franco I, Blick S et al: Laparoscopic Fowler-Stephens orchiopexy for the high abdominal testis. J Urol 1999; **162:** 990.
18. Baker LA, Docimo SG, Surer I et al: Multi-institutional analysis of laparoscopic orchiopexy. BJU Int 2001; **87:** 484.
19. Dhanani NN, Cornelius D, Gunes A et al: Successful outpatient management of the nonpalpable intra-abdominal testis with staged Fowler-Stephens orchiopexy. J Urol 2004; **172:** 2399.
20. Chang M and Franco I: Laparoscopic Fowler-Stephens orchiopexy: the Westchester Medical Center experience. J Endourol 2008; **22:** 1315.
21. Yucel SY, Ziada A, Harrison C et al: Decision making during laparoscopic orchiopexy for intra-abdominal testes near the internal ring. J Urol 2007; **178:** 1447.

EDITORIAL COMMENTS

Management of the intra-abdominal testis is among the more frustrating problems I encounter. I have tried conventional orchiopexy with extensive retroperitoneal dissection, staged orchiopexy with and without silicone sheeting, single and staged Fowler-Stephens procedures, laparoscopic orchiopexy with and without a Fowler-Stephens maneuver, and microvascular anastomosis of the spermatic vessels to the deep epigastric vessels. Only microvascular anastomosis has yielded consistently satisfactory results (a viable testis in good position in 90% of cases) but it is an involved and lengthy procedure that necessitates a skilled and proficient microvascular surgeon as part of a team. Consequently in my practice microvascular anastomosis is reserved for the patient with only 1 functioning testis that is intra-abdominal. I am surprised that the authors were able to visualize all of the intra-abdominal testes with ultrasound preoperatively because that has not been my experience. However, peeping testes that are in the inguinal canal on ultrasound can almost always be identified. Certainly the authors can follow the testes after the first and second stages with ultrasound to document size and vascularity. The procedure described is logical and, if the results can be replicated by others, could become a standard part of the armamentarium.

George W. Kaplan
Department of Pediatric Urology
University of California–San Diego School of Medicine
San Diego, California

The authors present an innovative approach to high undescended testes. They support our long maintained belief that the spermatic vessels and vas are not short in cryptorchidism—they are just embedded in the endopelvic fascia. Thus, extended mobilization by either laparoscopy or open surgery will almost always move high testes into the scrotum (reference 3 in article). Our success rate is better than 90%.[1] Careful attention to anatomy is important.

Among the cases reported, where the retroperitoneal attachments of the vessels and vas were stretched into a satisfactory scrotal position, success was achieved in 100% but a second operation was needed. The Fowler-Stephens approach, except in the rarest of cases, appears outmoded.

Howard M. Snyder, III
Division of Urology
University of Pennsylvania School of Medicine
Philadelphia, Pennsylvania

REFERENCE

1. Hutcheson JC, Cooper CS and Snyder HM III: The anatomical approach to inguinal orchiopexy. J Urol 2000; **164:** 1702.